

Application of Second-Generation Swept-Source Anterior Segment-OCT in the Measurement of Marginal Reflex Distance-I (MRD-I)

This article was published in the following Dove Press journal:
Clinical Ophthalmology

Kosuke Ogasawara 

Medical Corporation, Ogasawara Eye
Clinic, Morioka Iwate 020-0114, Japan

Purpose: To measure marginal reflex distance-1 (MRD-1) values in normal subjects and patients with blepharoptosis using second-generation swept-source anterior segment optical coherence tomography (AS-OCT) and to evaluate the usefulness of this measurement method.

Materials and Methods: MRD-1 values were measured using AS-OCT in 80 eyes of 40 normal subjects (16 men and 24 women) aged 20–59 years with no neurological or endocrinological disorders, and the measured values were compared between four age groups comprising 20 eyes of 10 subjects each in their 20s, 30s, 40s, and 50s. The Volk Eye Check system was simultaneously used to measure MRD-1 in 40 eyes of 20 normal subjects, and the measured values were compared with those obtained using AS-OCT. In 21 eyes of consecutive 13 involuntional blepharoptosis patients (48–84 years of age, mean 70.2 years), MRD-1 values were measured using AS-OCT preoperatively and 3 months after surgery to examine the rates of successful measurements as well as preoperative and postoperative results.

Results: The mean MRD-1 value using AS-OCT in 80 eyes of 40 normal subjects was 3.70 ± 0.10 mm, whereas the values in 20 eyes of 10 subjects each from the four different age groups were 4.01 ± 0.54 mm, 3.88 ± 0.60 mm, 3.96 ± 0.77 mm, and 2.94 ± 0.79 mm for subjects in their 20s, 30s, 40s, and 50s, respectively; significant differences were observed between the 50s group and other groups ($p < 0.01$). The mean MRD-1 values using AS-OCT and the Volk Eye Check system in 40 eyes of 20 normal subjects were 3.68 ± 0.70 mm and 3.71 ± 0.84 mm, respectively, with no significant differences ($p: 0.87$). The mean preoperative and postoperative MRD-1 values in patients with involuntional blepharoptosis were 0.29 ± 0.70 mm and 3.24 ± 0.92 mm, respectively; the rate of successful MRD-1 measurements using AS-OCT was 100% among trial subjects.

Conclusion: MRD-1 measurement using AS-OCT is a simple and reproducible method that allows the direct comparison of numerical values in normal subjects as well as in patients with blepharoptosis.

Keywords: blepharoptosis, MRD1, swept-source anterior segment-OCT

Correspondence: Kosuke Ogasawara
Ogasawara Eye Clinic, 3-10-12,
Takamatsu, Morioka Iwate 020-0114,
Japan
Tel +81 19 662 3223
Fax +81 19 662 7331
Email oga-koke@diamond.broba.cc

Introduction

With increasing age of the population, more patients are developing blepharoptosis, thus increasing the need for its surgical treatment each year. Blepharoptosis causes aesthetic issues and visual function problems, especially narrowed visual field.^{1–5}

International guidelines on the surgical treatment of blepharoptosis including preoperative evaluation and selection of the surgical procedure have not been established. Nevertheless, it is important to accurately measure the severity of

blepharoptosis before surgery. According to the recent AAO opinion,⁴ blepharoptosis surgery is functionally indicated when marginal reflex distance 1 (MRD-1) is ≤ 2 mm. Common methods to measure MRD-1 include the corneal reflex-based measurement using a ruler (clinical method)⁶ and calculation using digital photographs and image J software program (<http://rsbweb.nih.gov/ij>; digital method).⁷ Recently, the Volk Eye Check system⁸ and analogous methods^{9,10} have also been reported. In this study, we used the second-generation swept-source anterior segment optical coherence tomography (AS-OCT) (CASIA2, Tomey Corporation, Nagoya, Japan) to measure MRD-1 values in normal subjects and preoperative and postoperative MRD-1 values in patients with blepharoptosis to assess its usefulness.

Materials and Methods

This study included adults with blepharoptosis or normal eyelid position. Written informed consent was obtained from all the subjects. The study was conducted as per the tenets of the Declaration of Helsinki and with the approval of the medical corporation of Ogasawara Eye Clinic's ethical review board. Patients whose images and/or measurements appear in this publication provided additional written consent for publication of their photographs.

MRD-1 values were measured using AS-OCT in 80 eyes of 40 normal subjects (16 men and 24 women) aged 20–59 years who had no systemic diseases such as neurological and endocrinological disorders (Figure 1A). A snapshot taken during the measurement is shown in Figure 1B. MRD-1 values were measured as follows: (1) Images were separately taken for the left and right eyes in cataract preoperative measurement mode. Each subject placed his/her face on the chin support and fixed his/her eyes on a front orange fixation lamp with both eyes open naturally. (2) For analysis of MRD-1, an orthoptist clicked the front monitor and fixed the corneal reflex before adjusting the yellow line to 90°. (3) MRD-1 was automatically measured when the memory was placed on the superior palpebral margin and corneal apex. The measurements can be performed in a bright room. A typical example is shown in Figure 2. For patients whose superior palpebral margin was lower than the pupil center, the eyelid was elevated to confirm the pupil center and then returned to its original position before MRD-1 was measured (Figure 3).

The MRD-1 values measured using AS-OCT in normal subjects were compared to detect any significant difference

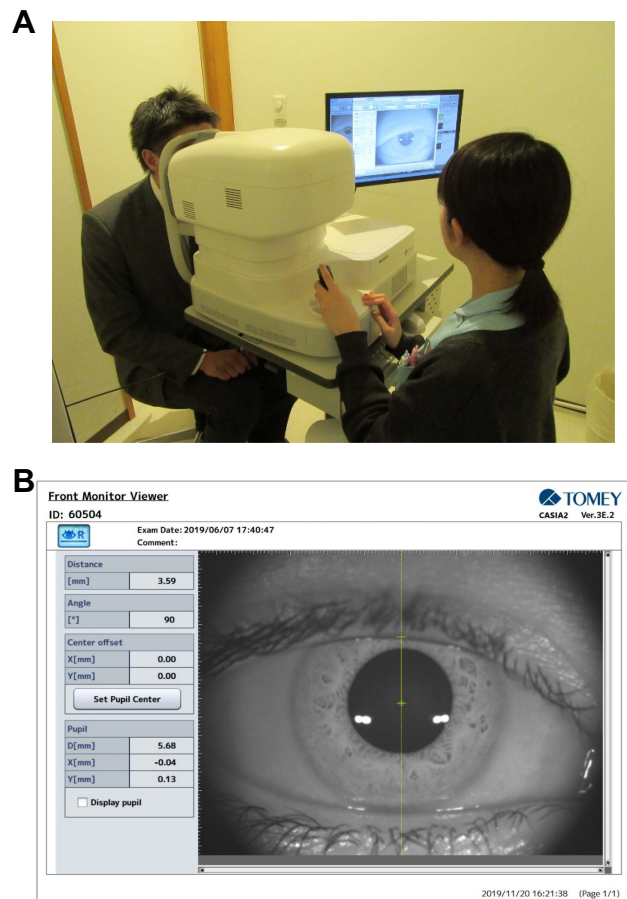


Figure 1 MRD-1 measurement scene using AS-OCT (A). A snapshot taken during the MRD-1 measurement screen using AS-OCT (B).

between the four age groups comprising 20 eyes of 10 subjects each in their 20s, 30s, 40s, and 50s.

For comparison, the Volk Eye Check system⁸ was simultaneously used to measure MRD-1 in 40 eyes of 20 normal subjects aged 20–59 years of age, mean 39.2 years.

As a prospective study, preoperative and postoperative MRD-1 values were measured using AS-OCT in 21 eyes of consecutive 13 patients with involuntional blepharoptosis (48–84 years of age, mean 68.6 years) to examine the rates of successful measurements, reproducibility, and values measured before and 3 months after surgery. The basic surgical procedure was a modified transconjunctival tuck-ing method that was reported by us.¹¹

In this study, *t*-test and analysis of variance (Bonferroni's method) were used to detect significant differences.

Results

In 80 eyes of 40 normal subjects, the mean of MRD-1 values measured using AS-OCT was 3.70 ± 0.10 mm. In

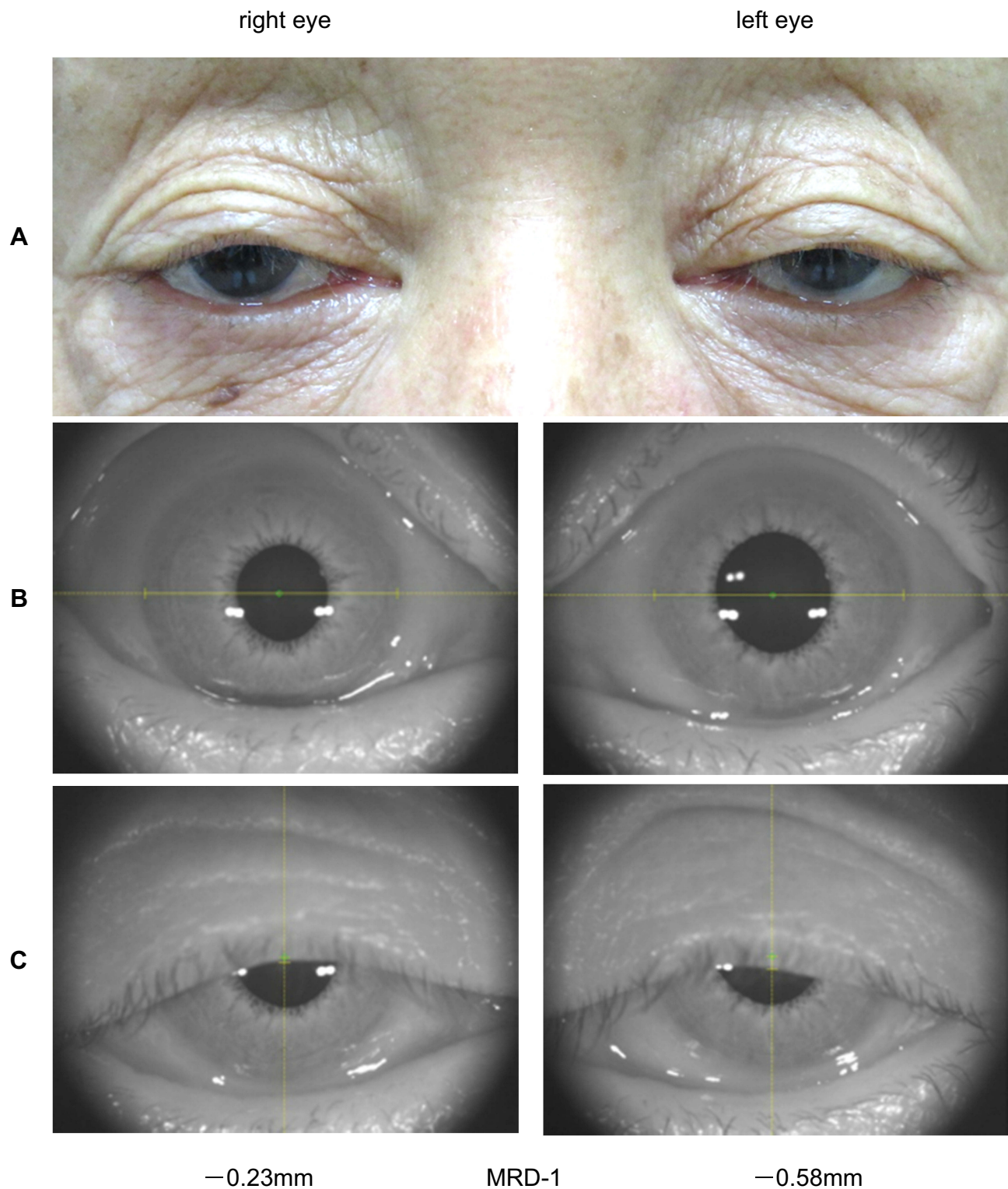


Figure 3 Photographs of eyelids of a patient with severe blepharoptosis (A), those being elevated to identify the pupil center (B), and those returned to the original position and subjected to MRD-1 measurement (C). A 84-year-old man; MRD-1, right: -0.23 mm, left: -0.58 mm.

preoperative examination, gonioscopic analysis, and observation of the filtration bleb after glaucoma surgery, analysis of sagittal images of upper eyelid¹⁴ as

well as corneal shape. In this study, we used AS-OCT functions to measure MRD-1 values in normal subjects and preoperative and postoperative MRD-1 values in

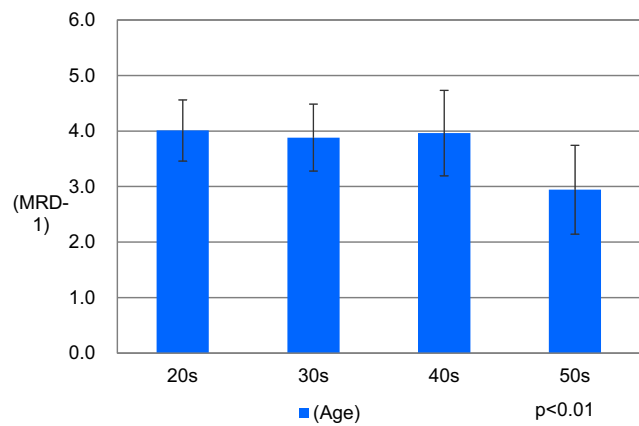


Figure 4 MRD-1 measurement data from 20 eyes of 10 normal subjects in their 20s–50s. Significant differences were observed between the 50s group and other groups by analysis of variance (Bonferroni's method). $F(3,76)=10.60$, $p<0.01$.

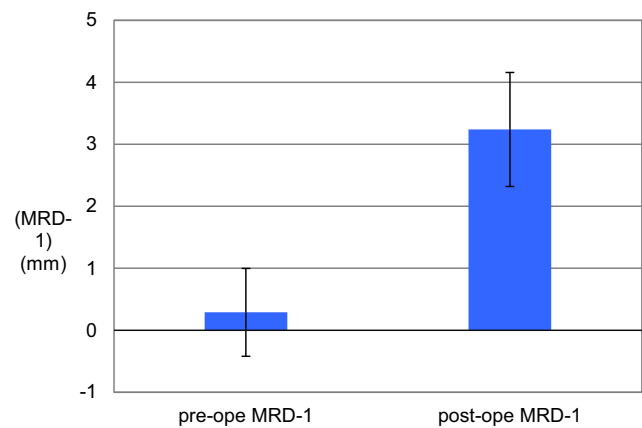


Figure 6 Preoperative (pre-op) and postoperative (post-op) MRD-1 measurements in patients included in this study. The mean MRD-1 values of pre-op and 3 months post-op were 0.29 ± 0.70 mm and 3.24 ± 0.92 mm, respectively.

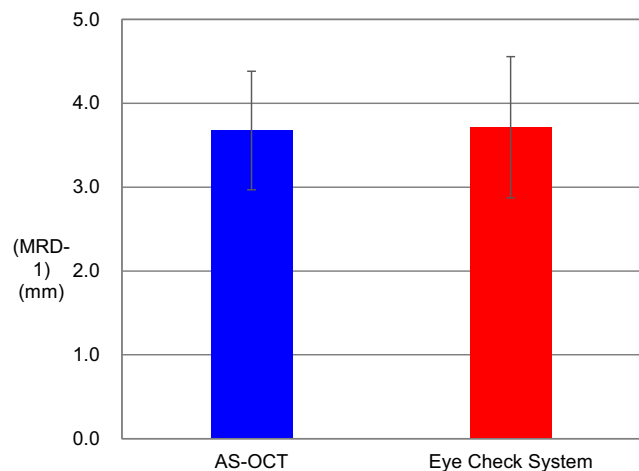


Figure 5 Results of MRD-1 measurement using AS-OCT and Volk Eye Check system in normal subjects. AS-OCT mean: 3.68 ± 0.70 mm, Volk Eye Check system mean: 3.71 ± 0.84 mm. No significant differences between the two methods were observed.

patients with blepharoptosis to examine the usefulness of AS-OCT.

This study revealed that MRD-1 could be measured using AS-OCT in a simple manner, measured MRD-1 values could be directly compared as numerical values, and AS-OCT could be used to measure MRD-1 values in normal individuals as well as preoperative MRD-1 values in patients with severe blepharoptosis. In addition, because the reproducibility of measured values was high, it appears that AS-OCT is a clinically significant MRD-1 measurement method.

Compared with the AS-OCT method used in this study, previously reported methods for MRD-1 measurement have some drawbacks. The disadvantages of the clinical

method include measurement errors as large as 0.5 mm^6 and a complicated process required for MRD-1 analysis, although ImageJ is probably the most popular image analysis software program. The ORBSCAN2 topography system is used to improve the accuracy of values determined with the ImageJ program;¹⁵ however, this method is associated with several biases and has a disadvantage of indirectly measuring MRD-1 values. Choi et al⁹ compared MRD-1 values obtained from ImageJ analysis of photographs taken with four different cameras and reported MRD-1 errors varying approximately 0.5–0.7 mm depending on the differences in cameras used and positional and size differences of flashbulbs used.

In this study, we compared MRD-1 values that were measured using AS-OCT and those measured using the Volk Eye Check system.⁸ The Volk Eye Check System is a modified smartphone intended to collapse the space between convenience of clinical and the precision of digital measurements. This device is outfitted with image processing software that automatically measures parameters such as MRD-1 in real-time using photographs taken by integrated camera. No significant differences between the two methods were noted in normal subjects (Figure 5). However, in patients with blepharoptosis, MRD-1 could be measured using the Volk Eye Check system only for $\leq 50\%$ of moderate to severe cases, and we could not compare the AS-OCT and Volk Eye Check system results in this population. Sinha et al¹⁶ compared the values measured using the clinical method, digital method, and Volk Eye Check system. Similarly to our results, they found no significant differences among the three groups in normal eyes. In patients with blepharoptosis, they found that the Volk

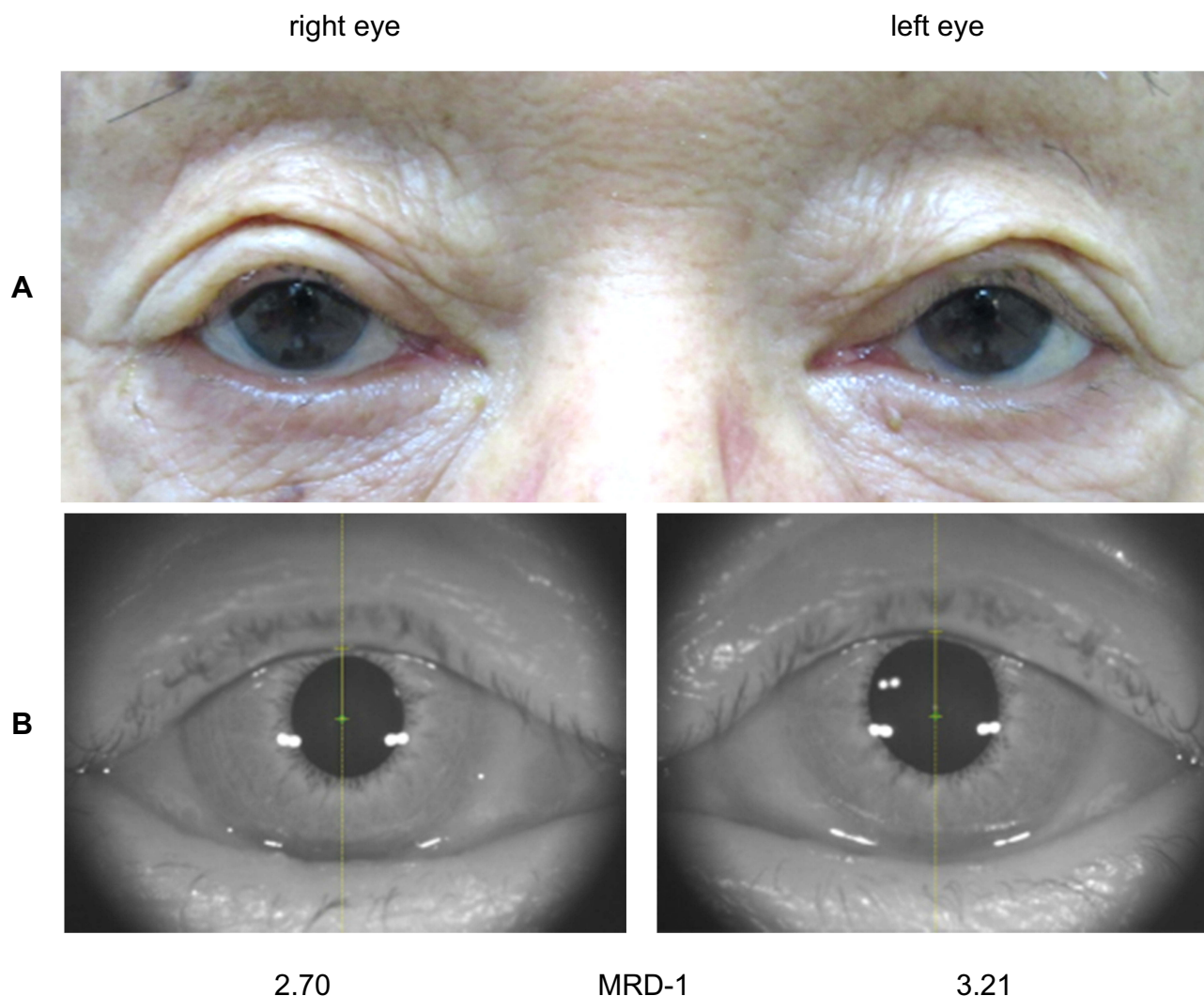


Figure 7 A photograph taken 3 months after surgery for severe blepharoptosis (**A**) and MRD-1 measured using AS-OCT (**B**) A 84-year-old man:MRD-1, right: 2.70 mm, left: 3.21 mm. Before surgery photographs are shown in [Figure 3](#).

Eye Check system overestimated the amount of blepharoptosis and the rate of successful measurements was approximately 66%. These and our data indicate advantage and superiority of AS-OCT compared to the Volk Eye Check System. Many Japanese individuals have thick eyelids that are shallow in depth and double eyelids are relatively minority. These characteristics may explain why software analysis of photographs is difficult (see a representative case in [Figure 8](#)). In AS-OCT measurement, there were concerns that the instrument might interfere with MRD-1 because it is placed right in front of the eyes. Our results indicate that this caused negligible errors, if any.

The AS-OCT method allows simple MRD-1 measurement even in moderate and severe blepharoptosis patients with a stable measurable rate of 100%. In addition, this

method may be useful to accurately and objectively assess the degree of recovery and postoperative course following blepharoptosis surgery. Furthermore, this method may be useful to identify unilateral blepharoptosis and compare the amounts of blepharoptosis between the left and right eyes.

Conclusions

MRD-1 measurement using AS-OCT is a simple and reproducible method that allows the direct comparison of numerical values. AS-OCT can be used to measure MRD-1 values for preoperative and postoperative values in patients with blepharoptosis. This measurement method might enable accurate and objective assessment of the degree of recovery and postoperative course following blepharoptosis surgery.

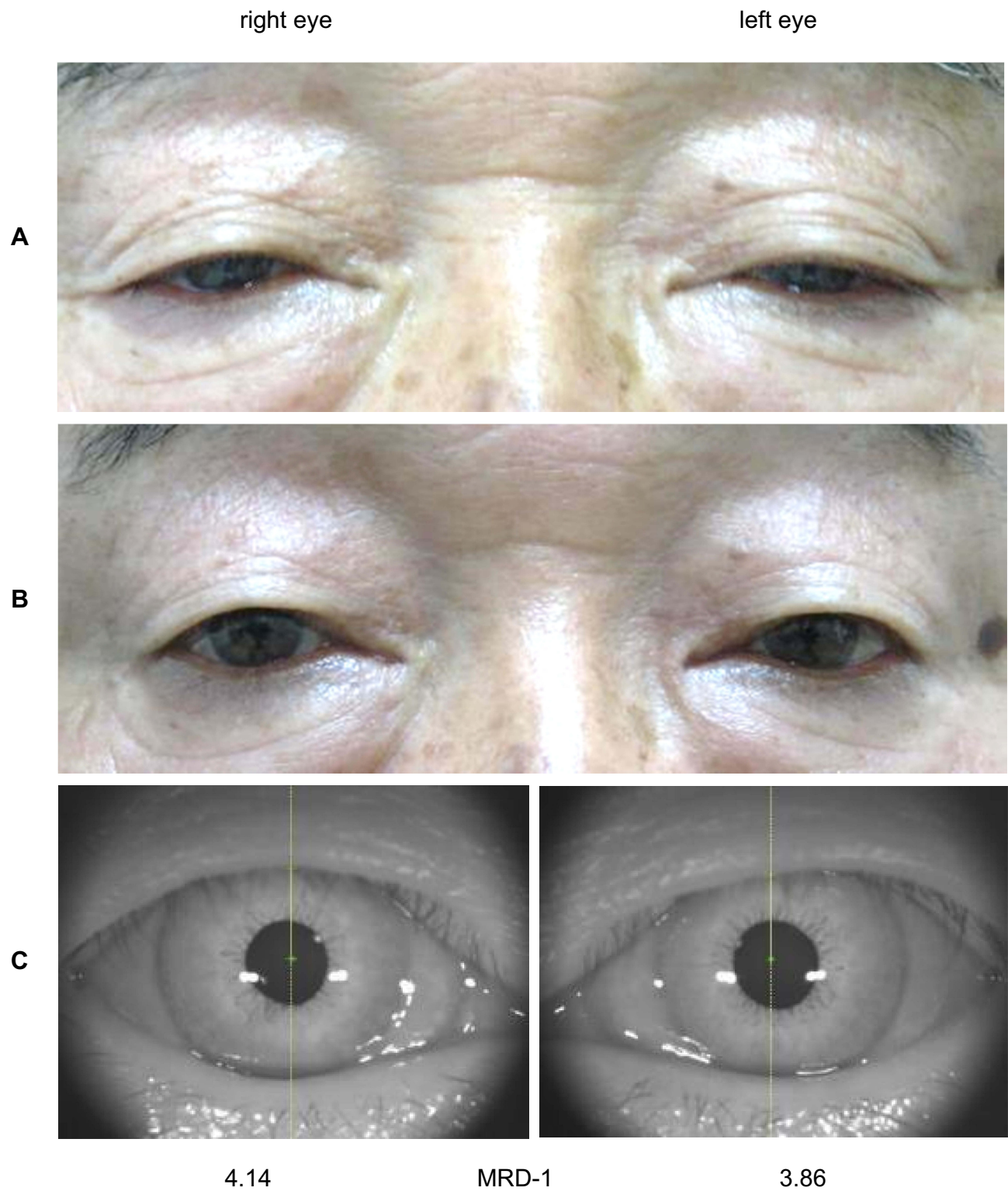

Figure 8 A photographs of eyelids of a 75-year-old male patient with severe blepharoptosis (**A**) and postoperative three months after surgery (**B, C**). Measuring MRD-I values by AS-OCT (**C**) are 4.14 mm in right eye and 3.86 mm in left eye. Preoperative MRD-I, right eye:-0.81 mm, left eye:-1.19 mm.

Disclosure

The author reports no conflicts of interest in this work.

References

- Battu VK, Meyer DR, Wobig JL. Improvement in subjective visual function and quality of life outcome measures after blepharoptosis surgery. *Am J Ophthalmol.* 1996;121:677–686. doi:10.1016/S0002-9394(14)70634-8
- Federici TJ, Meyer DR, Lininger LL. Correlation of the vision-related functional impairment associated with blepharoptosis and the impact of blepharoptosis surgery. *Ophthalmology.* 1999;106:1705–1712. doi:10.1016/S0161-6420(99)90354-8
- Ho SF, Morawski A, Sampath R, et al. Modified visual field test for ptosis surgery (Leicester Peripheral Field Test). *Eye.* 2011;25:365–369. doi:10.1038/eye.2010.210
- Cahill KV, Bradley EA, Meyer DR, et al. Functional indications for upper eyelid ptosis and blepharoplasty surgery: a report by the American Academy of Ophthalmology. *Ophthalmology.* 2011;118:2510–2517. doi:10.1016/j.ophtha.2011.09.029
- Pemberton JD, Salter M, Fay A, et al. Investigation of goldmann perimetry in evaluation of patients for upper eyelid blepharoplasty. *Orbit.* 2018;37:48–52. doi:10.1080/01676830.2017.1353115
- Boboridis K, Assi A, Indar A, et al. Repeatability and reproducibility of upper eyelid measurements. *Br J Ophthalmol.* 2001;85:99–101. doi:10.1136/bjo.85.1.99
- Choi CJ, Lefebvre DR, Yoon MK. Validation of the facial assessment by computer evaluation (FACE) program for software-aided eyelid measurements. *Orbit.* 2016;35:117–120. doi:10.3109/01676830.2016.1139595
- Volk Eye check—ocular measurement device. Available from: https://volk.com/media/wysiwyg/pdf/ifu/IM-078/IM-078_English.pdf. Accessed July 5, 2017.
- Choi CJ, Chou JC, Lefebvre DR, et al. Margin reflex distance: differences based on camera and flash positions. *Ophthalmic Plast Reconstr Surg.* 2016;32:199–203. doi:10.1097/IOP.0000000000000456
- Rüfer F, Schröder A, Erb C. White-to-white corneal diameter: normal values in healthy humans obtained with the Orbscan II topography system. *Cornea.* 2005;24:259–261. doi:10.1097/01.icc.0000148312.01805.53
- Ogasawara K. Ptosis surgery with an improved method of shortening the Müller's muscle and the levator aponeurosis with transconjunctival threading. *J Ophthalmic Surg.* 2019;2:7–12.
- Tomey Corporation. Fourier domain OCT CASIA2. Available from: http://tomey.de/images/product_flyer/CASIA2_br_w.pdf. Accessed November 21, 2017.
- Xu BY, Mai DD, Penteado RC, et al. Reproducibility and agreement of anterior segment parameter measurements obtained using the CASIA2 and spectralis OCT2 optical coherence tomography devices. *J Glaucoma.* 2017;26(11):974–979. doi:10.1097/IJG.0000000000000788
- Zheng X, Goto T, Shiraishi A, et al. New method to analyze sagittal images of upper eyelid obtained by anterior segment optical coherence tomography. *Orbit.* 2019;38(6):446–452. doi:10.1080/01676830.2018.1563200
- Rajyalakshmi R, Prakash WD, Ali MJ, et al. Periorbital biometric measurements using ImageJ software: standardisation of technique and assessment of intra- and interobserver variability. *J Cutan Aesthet Surg.* 2017;10:130–135. doi:10.4103/JCAS.JCAS_61_17
- Sinha KR, Yeganeh A, Goldberg RA, et al. Assessing the accuracy of eyelid measurements utilizing the Volk eye check system and clinical measurements. *Ophthalmic Plast Reconstr Surg.* 2018;34:346–350. doi:10.1097/IOP.0000000000000991

Clinical Ophthalmology

Dovepress

Publish your work in this journal

Clinical Ophthalmology is an international, peer-reviewed journal covering all subspecialties within ophthalmology. Key topics include: Optometry; Visual science; Pharmacology and drug therapy in eye diseases; Basic Sciences; Primary and Secondary eye care; Patient Safety and Quality of Care Improvements. This journal is indexed on PubMed

Central and CAS, and is the official journal of The Society of Clinical Ophthalmology (SCO). The manuscript management system is completely online and includes a very quick and fair peer-review system, which is all easy to use. Visit <http://www.dovepress.com/testimonials.php> to read real quotes from published authors.

Submit your manuscript here: <https://www.dovepress.com/clinical-ophthalmology-journal>